

# Pediatric Bone Scintigraphy Update

Helen R. Nadel, MD, FRCPC (Diag Rad) (Nuc Med), ABR (Diag Rad) (Ped Rad), ABNM

**Bone scintigraphy is a sensitive tool to evaluate the musculoskeletal system in children. Hybrid imaging using computed tomography (CT) in combination with conventional bone scan and single photon emission computed tomography improves specificity and diagnostic accuracy. It also improves laboratory efficiency and may save the patient an additional visit to the hospital for a separate cross-sectional imaging study. We have found this technique to be particularly helpful in localizing a cause for pain in children who are nonverbal and to better delineate small bone and soft-tissue lesions that can occur with diagnoses of trauma, infection, and tumor. Special attention to technique of positioning the patient for potential CT examination is an adaptation that must be made by the technologist. Because of radiation concerns of the additional CT, obviously these examinations should be tailored to the individual child and be performed for limited sites directed to the abnormality observed on the associated single photon emission computed tomography examination or directed by the appropriate history.**

**Semin Nucl Med 40:31-40 © 2010 Elsevier Inc. All rights reserved.**

Bone scintigraphy still remains one of the most common indications for radionuclide examination in children. It is a sensitive examination to identify alterations in bone metabolism for any cause, but because of this nonspecificity the findings obtained from the scintigraphic examination must be correlated with the patient's clinical history and appropriate conventional and cross-sectional imaging. With the development of hybrid imaging in nuclear medicine, particularly single-photon emission computed tomography (SPECT/CT), this is now a reality for obtaining the pertinent correlative imaging in a single study in the nuclear medicine department.

There have been several excellent reviews of bone scintigraphy since pediatric bone update was reported in this journal in 2007.<sup>1-4</sup> This current update is to identify some of the differences in evaluating the skeletal system in children and to highlight how hybrid imaging has been incorporated into the evaluation to diagnose musculoskeletal disorders in children.

## Technical

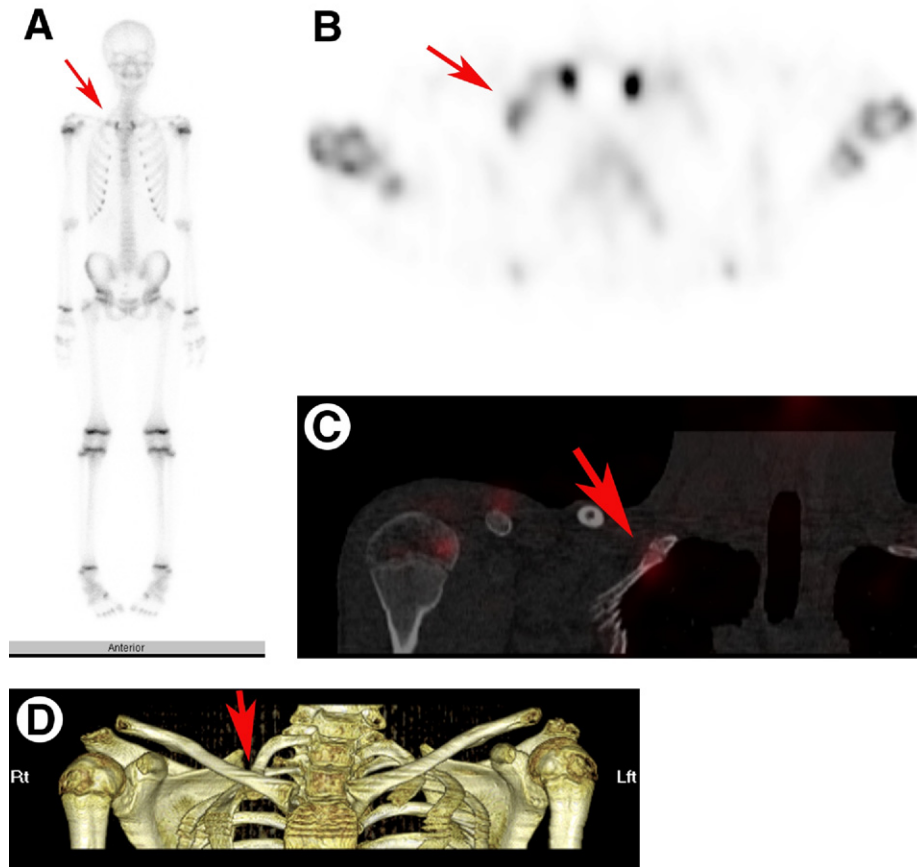
In our department sedation is not routinely employed when performing bone scintigraphy. However, in certain instances

children who are neurodevelopmentally delayed may require sedation for the procedure to be performed. In those instances, a pediatric anesthesiologist and their team handle all sedation, and it is their decision as to whether conscious sedation or general anesthesia is performed. The sedation process is usually only applied to the delayed imaging phase. In all instances, the child is fully monitored during the procedure and is recovered by nursing staff before being discharged home.

Administered radiopharmaceutical dose is usually weight-based. There has been some attempt to standardize the administered dose of radiopharmaceutical. The European Association of Nuclear Medicine has published their pediatric dose card on the basis of a multiple of baseline activity depending on the weight of the child to obtain weight-independent effective dose measurements for administered activity. The calculation for administered activity in MBq is baseline activity  $\times$  multiple depending on weight with minimum of 40 MBq administered activity.<sup>5</sup> The European Association of Nuclear Medicine website has the dosage card for all common radiopharmaceuticals and recommended administered radiopharmaceutical doses in children.<sup>6</sup> North American pediatric centers have recently been surveyed on their administered doses and have shown variability in the administered dose of radiopharmaceutical.<sup>7</sup> Our current recommendation for administered dose of <sup>99m</sup>Tc-methylene diphosphonate (<sup>99m</sup>Tc-MDP) for bone scintigraphy is 0.2-0.3 mCi/kg with a minimum dose of 3 mCi and maximum dose of 15 mCi.

A physician screens all requests for scintigraphic examination before an examination booking is made. At that

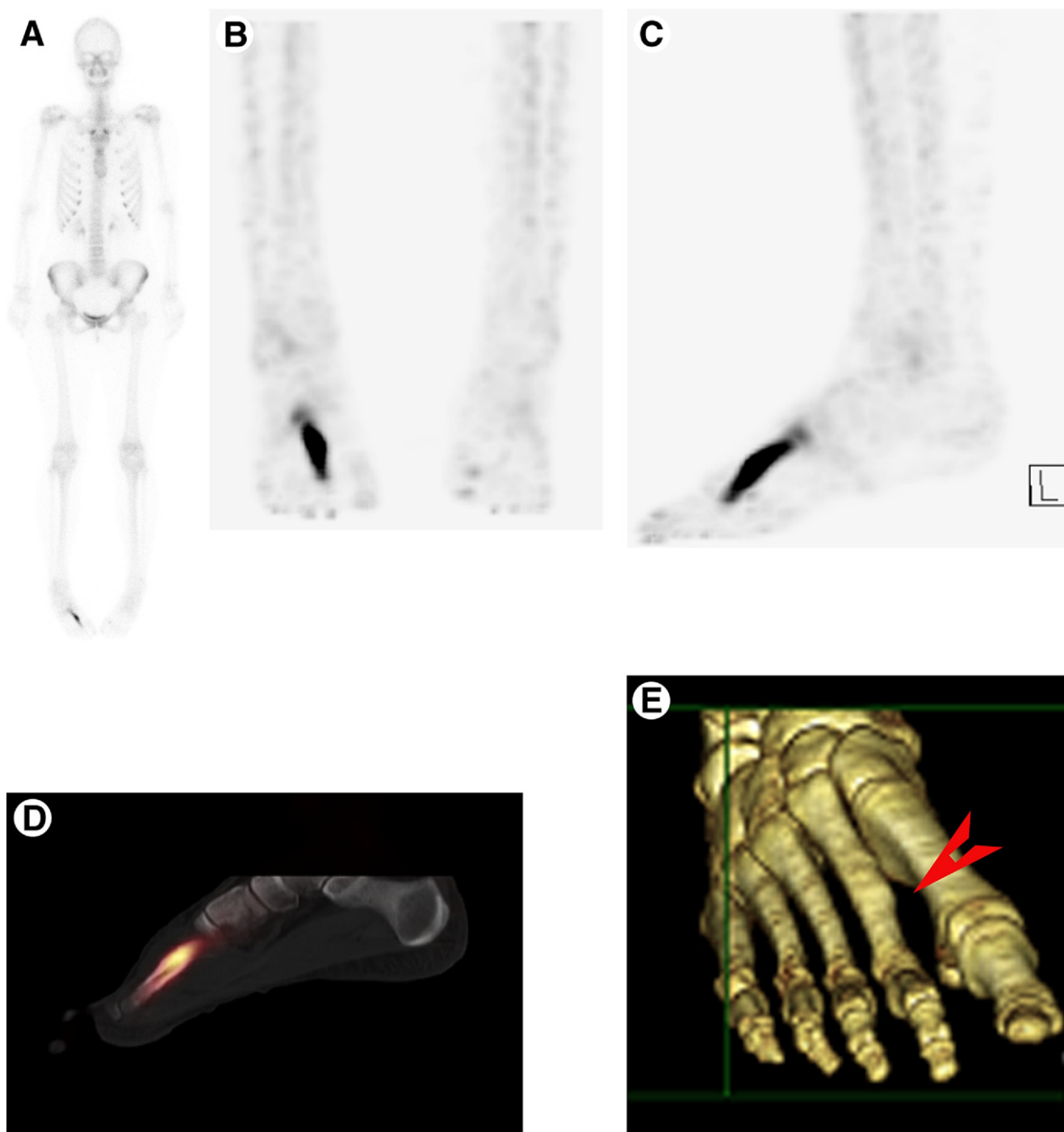
Division of Nuclear Medicine, Department of Radiology, British Columbia Children's Hospital, University of British Columbia, Vancouver, Canada. Address reprint requests to Helen R. Nadel, MD, FRCPC (Diag Rad) (Nuc Med), ABR (Diag Rad) (Ped Med), ABNM, Department of Nuclear Medicine, British Columbia Children's Hospital, 4480 Oak St, Vancouver, BC V6H 3V4, Canada. E-mail: hnadel@cw.bc.ca



**Figure 1** (A) A 12-year-old male with swelling noted in right supraclavicular area. Whole-body bone scintigraphy showed an area of mild delayed increased activity in the right supraclavicular area lateral to the sternoclavicular junction (arrow). (B) Maximum intensity projection (MIP) image of bone SPECT in axial plane better defines the focal abnormality (arrow). (C) Fused coronal SPECT/CT identifies that the increased activity is due to developmental variant of congenitally fused first and second rib. (D) CT performed for the SPECT/CT study is processed as a 3D volume rendered reconstruction, and clearly identifies the congenital rib fusion abnormality that appears as an area of increased activity on the bone scan (arrow).

time, the examination technique is tailored by notation on the requisition, to answer the diagnostic question and to instruct the technologist as to whether the study has immediate and delayed imaging, where SPECT might be performed, and if there is a likelihood of additional coregistered CT and if that CT study is likely to require an intravenous contrast administration. After the administering of the radiopharmaceutical to the patient, whole-body imaging is always performed. We do not perform limited regional bone scan examinations in children. In most bone scan examinations the study is performed with immediate blood pool imaging often of the whole-body as an anterior/posterior whole-body pass and then subsequent delayed whole-body imaging after a delay of 2-3 hours post injection of  $^{99m}\text{Tc}$ -MDP. SPECT is routinely used to further evaluate the area of suspected abnormality as directed by history or to define an abnormality observed on planar imaging in any part of the body including hands and feet. The acquisition is performed with a high-resolution collimator and using a  $128 \times 128$  matrix, SPECT is acquired with a noncircular orbit with 30 seconds per stop, iterative

reconstruction is performed on the SPECT study, and resolution recovery software is employed when the study is reconstructed. The addition of CT to the study is usually suggested when the examination request is triaged by the nuclear medicine physician, but the actual decision to perform additional CT is not made until the planar and SPECT imaging is reviewed with the patient still on the table during the time of the examination. For bone scintigraphy usually noncontrast, nonattenuation correction CT scan is performed of the area of interest using limited CT acquisition to the area of abnormality on the bone scan to minimize exposure to the patient. The parameters for acquisition of the CT study would be similar to those used for conventional stand-alone CT study. Dose modulation is applied to all CT acquisitions. Images are reconstructed and displayed in multiple formats for both fused and unfused images. All advanced processing that can be performed for conventional CT can be applied to CT images acquired on a multislice SPECT/CT hybrid device. The quality of the images will depend on the slice thickness of the acquisition and the resolution parameters that the CT

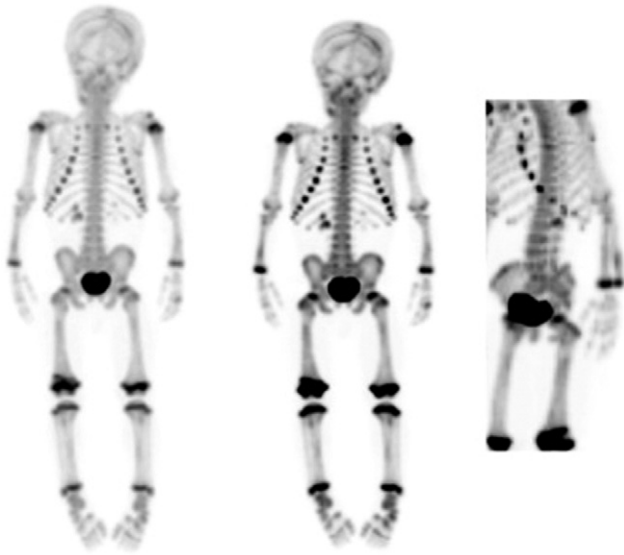

**Figure 2** (A) Whole-body bone scan performed in a teenager with foot pain shows focal increased activity in the right foot second metatarsal. Positioning for the whole-body bone image has the feet internally rotated. (B) Coronal MIP SPECT and (C) sagittal MIP SPECT. In these images the feet are positioned without internal rotation for SPECT so that they will be correctly oriented for CT imaging. (D) Sagittal fused SPECT/CT multiplanar reformations. The SPECT/CT confirms the presence of healing stress fracture in the left second metatarsal bone. (E) 3D CT reconstructed from the SPECT/CT acquisition shows the cortical thickening at the site of the healing fracture in the second metatarsal.

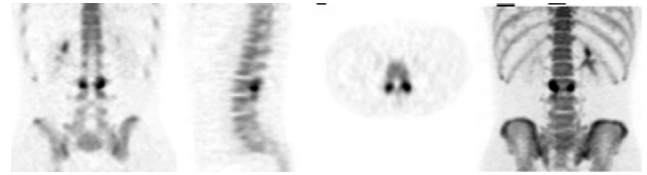
scanner device can provide (Figs. 1 and 2). A single comprehensive report is provided for both the bone scan examination and the CT scan study.

If it is anticipated that CT might be added to the examination then careful attention must be made by the technologist to ensure that there are no artifacts such as metal in the anticipated

field of view at the start of the SPECT acquisition as the patient cannot be moved between the SPECT and CT acquisition to ensure the best possible fusion is obtained of the 2 studies. Positioning of feet for SPECT in particular needs to be in the same position as would be used for routine CT evaluation of the feet (Figs. 1 and 2).



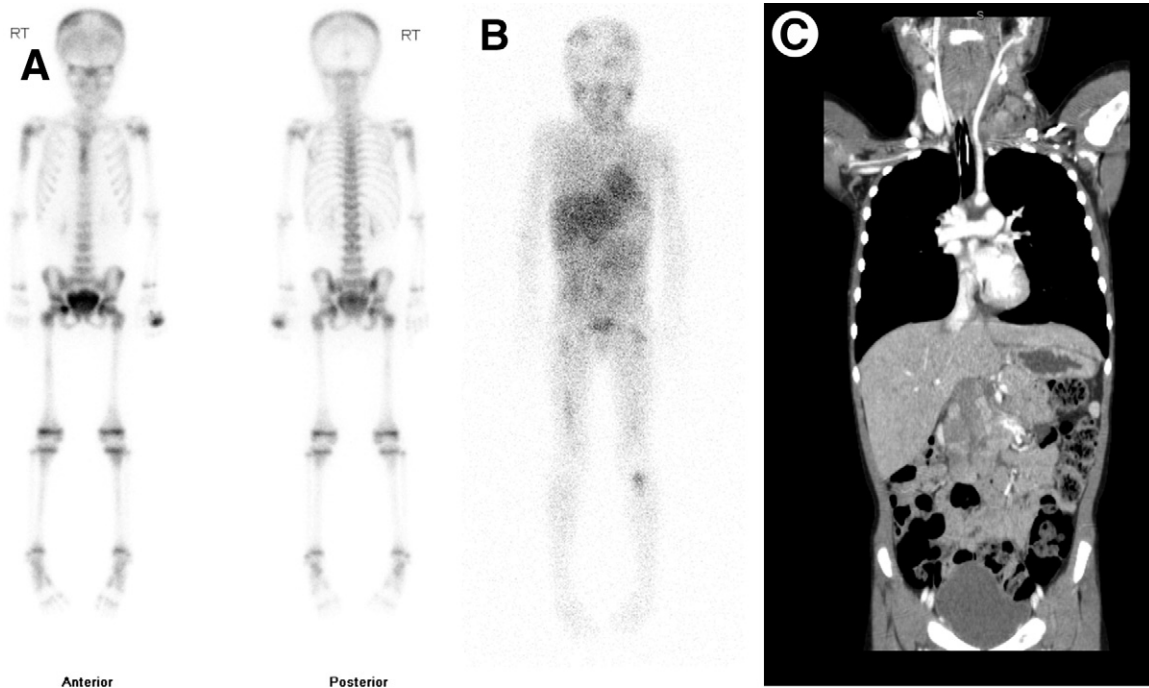
**Figure 3**  $^{18}\text{F}$ -sodium fluoride whole-body bone scan images of 8 months old infant showing multiple abnormal areas of increased activity involving upper and lower extremities, and left scapular spine representing multiple fractures, in keeping with the diagnosis of nonaccidental injury. (Images courtesy of Dr Ted Treves, Boston Children's Hospital.)



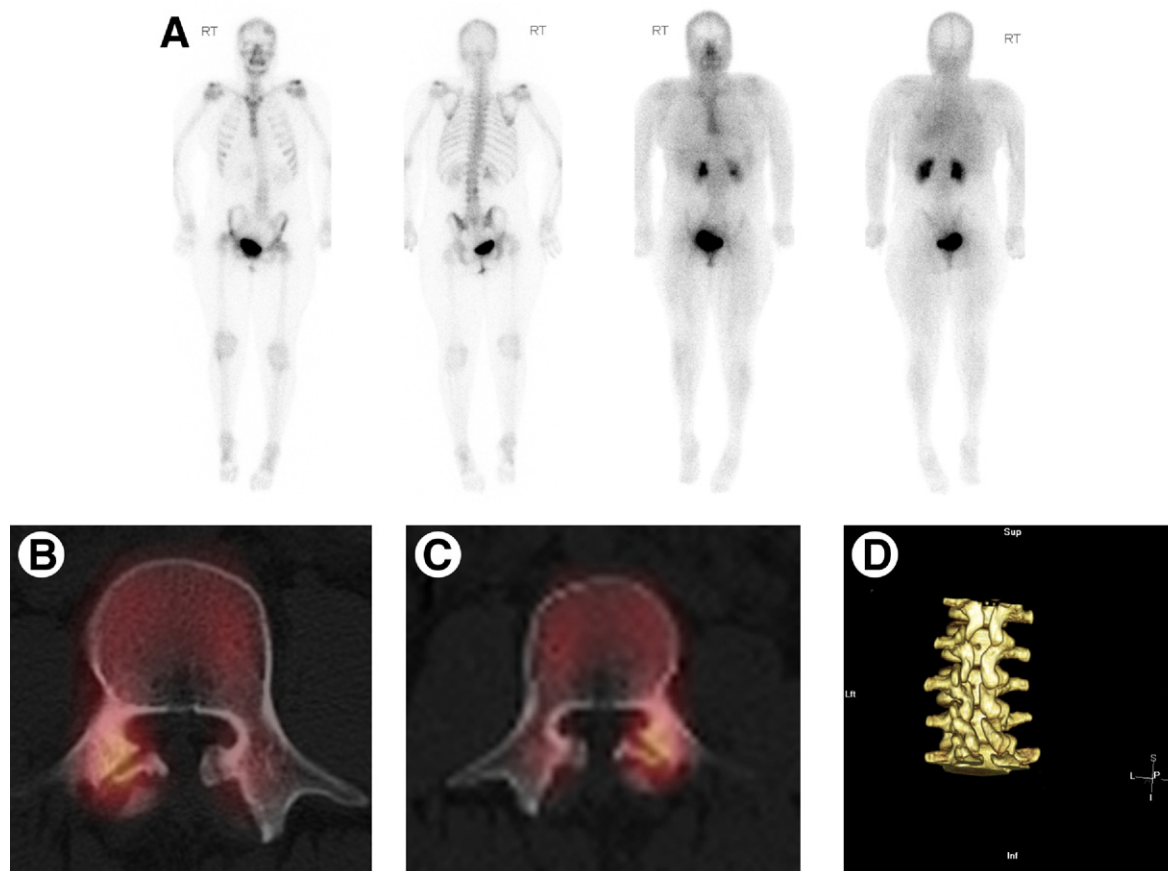
**Figure 4** Multiplanar  $^{18}\text{F}$ -sodium fluoride bone scan images in child with back pain showing increased activity in bilateral L3 pars interarticularis. (Images courtesy of Dr Ted Treves, Boston Children's Hospital.)

## $^{18}\text{F}$ -Sodium Fluoride Bone Scintigraphy in Children

With the increased availability of positron emission tomography (PET) imaging in children and the current shortage of  $^{99\text{m}}\text{Tc}$ -based radiopharmaceuticals, there may be more potential for using  $^{18}\text{F}$ -PET/CT bone scans in children. No specific preparation is required. The scan is usually performed 60 minutes post injection of the radiopharmaceutical but the window available for scanning is from 30 minutes to 4 hours to obtain high quality images.<sup>8,9</sup> Lim et al<sup>10</sup> performed 94  $^{18}\text{F}$ -sodium fluoride PET bone scans in teenagers and young adults and was able to discern causes for the back pain in 55% using this technique. Scan was performed 30 minutes after injection of the radiotracer, hence shortening the time of the study



**Figure 5** (A) Child presenting with multiple fractures. A whole-body bone scan shows abnormal activity diffusely in the skull, right humerus, around pelvis and proximal femora, and spine. Findings are suspicious for systemic disease, such as neoplasm. Neck mass confirmed on ultrasound and found at biopsy to represent neuroblastoma. (B) Staging  $^{123}\text{I}$  meta-iodobenzylguanidine scan confirms the multiple bony areas of involvement and shows abnormal activity in left neck and in abdomen compatible with the diagnosis of stage 4 neuroblastoma. (C) Coronal CT scan reconstructed image shows left neck soft tissue mass displacing vascular structures. There is a midline abdominal mass arising from the right suprarenal area and nodal disease in the mid abdomen. Bone windows (not shown) confirmed bony lesions observed on bone scan.



**Figure 6** Child with cerebral palsy who has pain in back but is not able to verbally communicate site of pain. (A) Whole-body imaging shows scoliosis and a focal lesion at the right side of mid lumbar spine. SPECT/CT confirmed bilateral spondylolysis with increased activity. (B) Fused SPECT/CT shows a spondylolysis with focal increased activity in the right L3 pars. (C) Fused SPECT/CT shows a spondylolysis with focal increased activity in the left L4 pars. (D) 3D-CT image shows deficiency of posterior spinous processes in the lumbar spine from previous laminectomy that may have produced the altered stress that led to development of the bilateral spondylolysis.

compared with conventional MDP bone scan. They found the images to be of higher resolution than MDP bone scan with similar radiation dosimetry. The cost was higher for the PET study but this may be offset by increased throughput and current increased cost of  $^{99m}\text{Tc}$ -based radiopharmaceuticals (Figs. 3 and 4).

## Indications

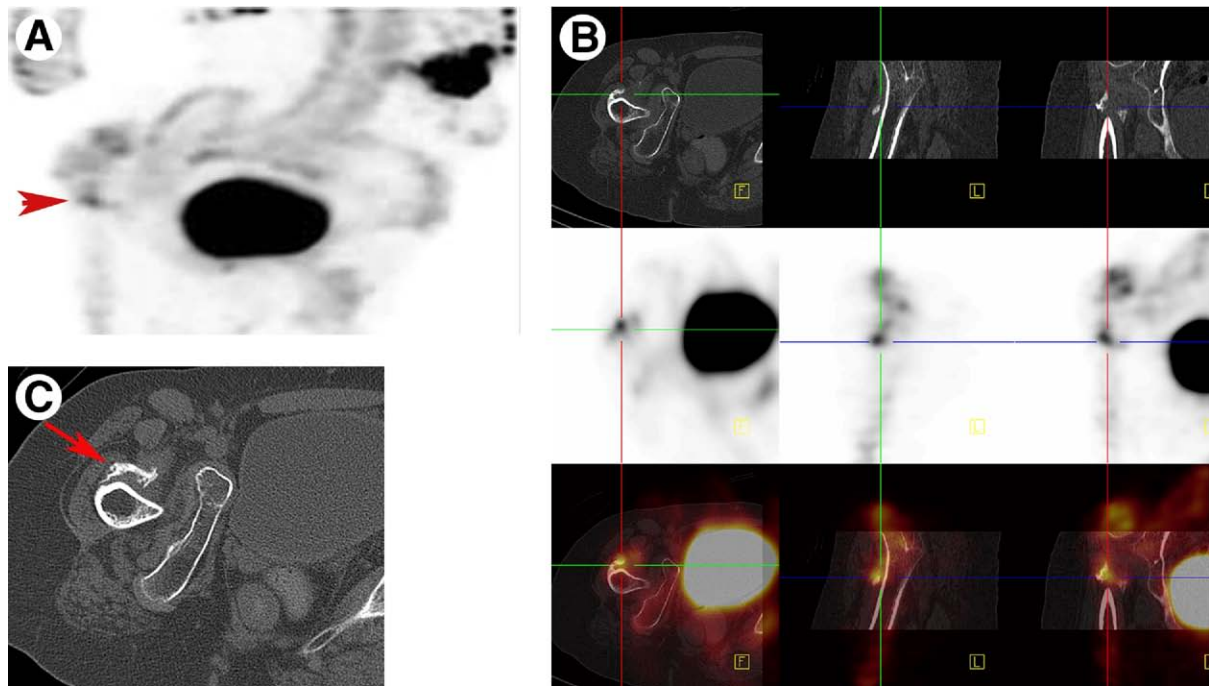
A limp, painful limb or back, suspected occult trauma, and suspected infection or inflammation for benign indications and staging or metastatic workup in a child with known malignancy are the common indications for bone scintigraphy in children. The bone scan examination is very sensitive but has low specificity and must be correlated with patient history and physical findings and then further diagnostic or pathologic investigation may be needed in any individual child.<sup>4</sup> Findings on bone scintigraphy performed for unexplained pain may be the first indication of a systemic illness or neoplasm (Fig. 5). For primary bone tumors bone scintigraphy is 100% sensitive but now may be replaced by PET/CT for staging evaluation.

## Trauma

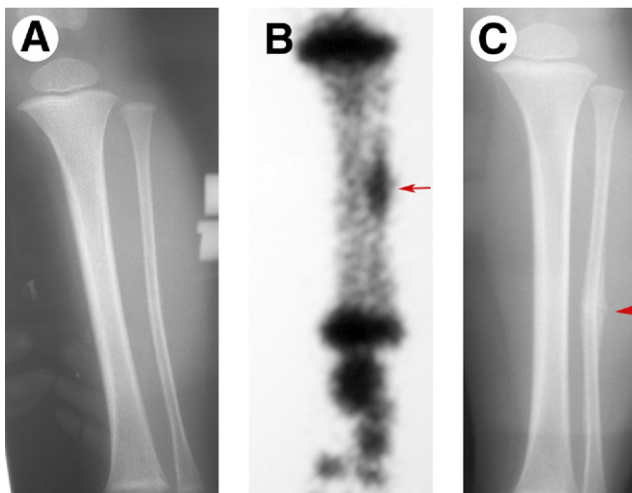
Even though it is rare for the bone scan to be the first study in a child with trauma, there are some instances where bone scintigraphy may be helpful in revealing injury that is not defined by conventional radiographs.<sup>3</sup> This is particularly helpful in non-verbal neurodevelopmentally delayed children who are not able to verbalize and localize the site of pain. The bone scan provides a total body screen that is sensitive to detect the site of bone or soft tissue abnormality and then often the addition of SPECT/CT can provide accurate diagnosis (Figs. 6 and 7). Toddler's fractures can occur from pelvis to feet and can be difficult to diagnose with conventional radiographs. The bone scan will identify the site of injury (Fig. 8).

## Nonaccidental Injury

The bone scan plays a complementary role to the radiographic skeletal survey that is mandatory in all children suspected of nonaccidental injury particularly under 2 years of age.<sup>11</sup> All areas of abnormality identified on bone scintigra-



**Figure 7** Nonverbal child with cerebral palsy who seems to be in pain clinically. Bone scan is performed in an attempt to localize the pain. Due to severe scoliosis, the patient is difficult to position and the anatomy is distorted. SPECT of the pelvis is performed as the patient seems to be clinically in pain when the pelvis is manipulated. A dynamic review of the SPECT MIP images when the patient is still undergoing the study suggests that there is a focus of increased activity in the right femoral neck area. Without repositioning the patient a noncontrast, nonattenuation CT scan of the right hip area is acquired. (A) SPECT MIP image of the pelvis shows focal abnormality in the area of the right femoral neck suggesting a possible right femoral neck fracture (arrowhead). (B) SPECT/CT images confirm the focal area of increased activity in the right upper thigh is in the soft tissues anterior to the femoral neck in an area of myositis ossificans. (C) CT image showing the area of myositis ossificans anterior to the femoral neck (arrow).

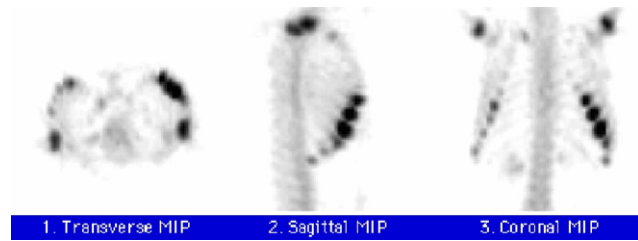


**Figure 8** (A) Fourteen month old male brought to the emergency department by his father twice in a 48 hour period as he is refusing to put weight on his left leg. Radiograph of the left tibia does not show obvious fracture. (B) Anterior spot image of bone scan shows focal abnormality of the mid left fibula (arrow) compatible with an occult toddler type fracture. Toddler type fracture can occur from spine to small bones of feet and is considered a repetitive stress injury on normal bone. It usually occurs just as young children are learning to weight-bear and exerting abnormal biomechanical stress on the bones of the lower extremities. (C) Follow-up radiograph shows periosteal reaction in the mid left fibula (arrowhead) in keeping with healing fracture.

phy must be evaluated with radiographs. In addition, the bone scan is insensitive in detecting skull abnormalities and skull radiographs must always be obtained. The bone scan is particularly sensitive to detecting injury in the small joints of hands and feet. It may also detect injury that is difficult to visualize in flat bones, such as scapula and pelvis. Careful attention to technique is required. The images must be magnified as appropriate and single bone or extremity imaging should be obtained as coned spot views often in 2 projections rather than whole-body single pass anterior and posterior views in young infants. It is our routine to perform whole-body blood pool and delayed imaging with SPECT of the thorax. Posterior contiguous rib fractures that are often pathognomonic of “shaken babies” are easily observed on SPECT imaging. CT study combined with SPECT has proven helpful to delineate small lesions in ribs or flat bones (Figs. 3 and 9).

## Back Pain in Children

SPECT/CT has been particularly helpful in the investigation of children with back pain. The differential diagnosis often includes spondylolysis as a cause of the pain (Fig. 6). With coregistered SPECT/CT a single study can be performed thus eliminating the need for an additional visit to the hospital for CT scan at a separate time. Other conditions that are often



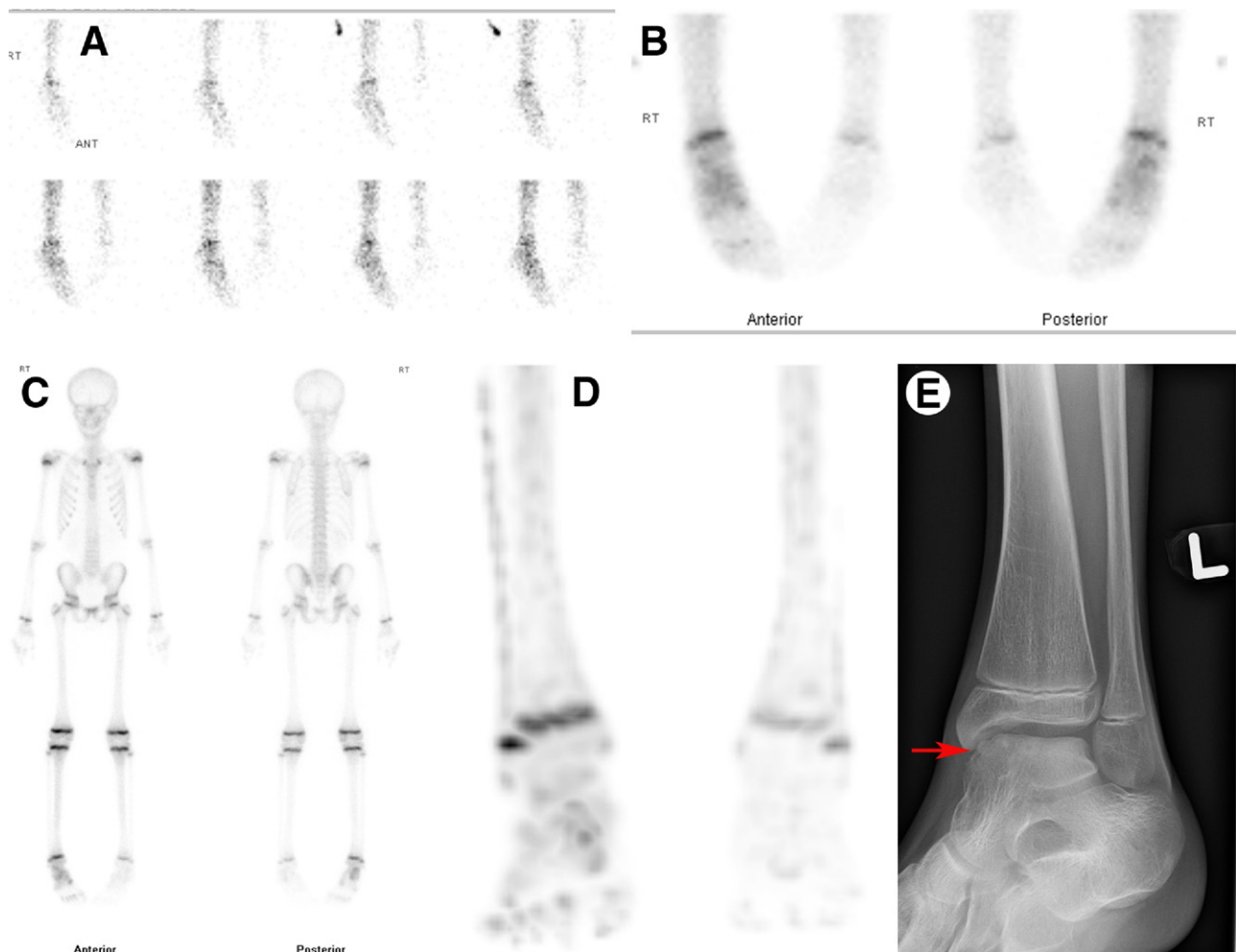
**Figure 9** SPECT MIP multiplanar images from bone scan in infant who presents with an abnormal head CT. Multiple contiguous left anterior rib fractures compatible with nonaccidental injury. (Color version of figure is available online.)

diagnosed include enthesitis of ligaments attached to spinous processes in athletic children; compression fractures and other ligamentous injuries associated with avulsion of iliac spines either anterior superior iliac spine or anterior inferior iliac spine and transitional vertebrae that may be a source of bone stress. Transitional vertebrae at the lumbosacral junction can often be a cause of bone pain in children. SPECT/CT

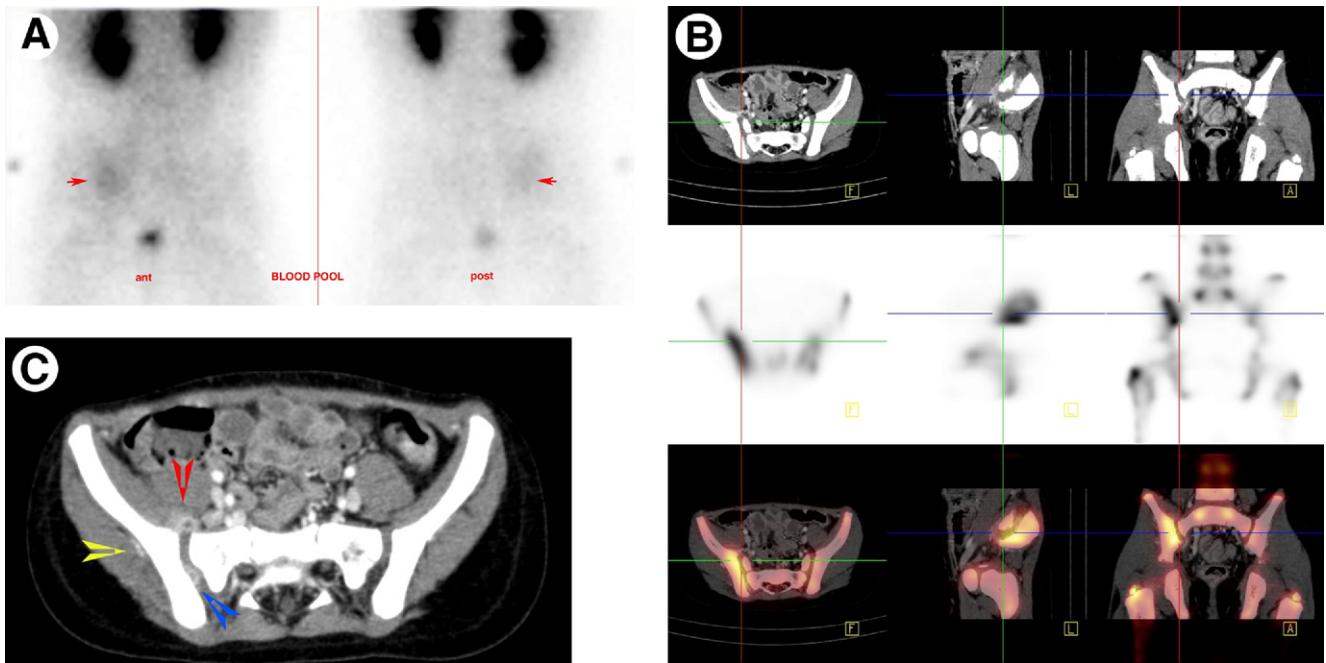
can identify these variations of normal and can often show increased activity on the bone scan if there is abnormal biomechanical stress causing bone reaction at these areas. SPECT/CT can also be helpful in the identification of other developmental variants (Fig. 1).

### Chronic Regional Pain Syndrome

Chronic regional pain syndrome is characteristically diagnosed on bone scintigraphy. In contrast to adult forms of this diagnosis, children often have a “cold variant” of this entity in which both the immediate and delayed phase of bone scintigraphy show decreased activity in the affected limb. The abnormality can be recognized in children who have open epiphyses by the incongruence of the involved epiphyseal plate activity compared with remote ipsilateral and contralateral epiphyseal plate activity to ensure the “correct” side of involvement is appreciated.<sup>12,13</sup> (Fig. 10).



**Figure 10** (A) Blood flow, (B) blood pool, (C) delayed bone scan, and (D) MIP coronal SPECT bone scan images showing 3 phase and SPECT diffuse decreased activity in the left foot and ankle. (E) The radiograph of her left foot shows abnormality suggestive of osteochondritis dissecans of the dome of the talus with an area of sclerosis and lucency noted (arrow) but no focal increased activity is observed in this area on the conventional bone scan or on the correlative SPECT/CT. Her pain is likely due to chronic regional pain syndrome. (Color version of figure is available online.)



**Figure 11** Fifteen month old female who has just returned from a tropical vacation presents with fever and limp. (A) Posterior planar blood pool images of the pelvis shows hyperemia in the right sacroiliac area. The hyperemia is more prominent anteriorly than posteriorly. (B) Post-intravenous contrast enhanced CT scan of the pelvis coregistered to the SPECT examination identifies increased activity in the right sacroiliac joint area. (C) Postcontrast CT scan shows a ring-enhancing lesion in the right iliacus muscle area in keeping with soft tissue abscess (red arrowhead), and within the SI joint itself (blue arrowhead) and lateral to the ilium with bone involvement (yellow arrowhead). The bone scan examination performed with hybrid SPECT/CT technology with the CT performed as postcontrast diagnostic CT scan helped to establish the diagnosis of osteomyelitis of bone, septic arthritis of the right sacroiliac joint and soft tissue cellulitis, and focal abscess in muscle.

## Infection

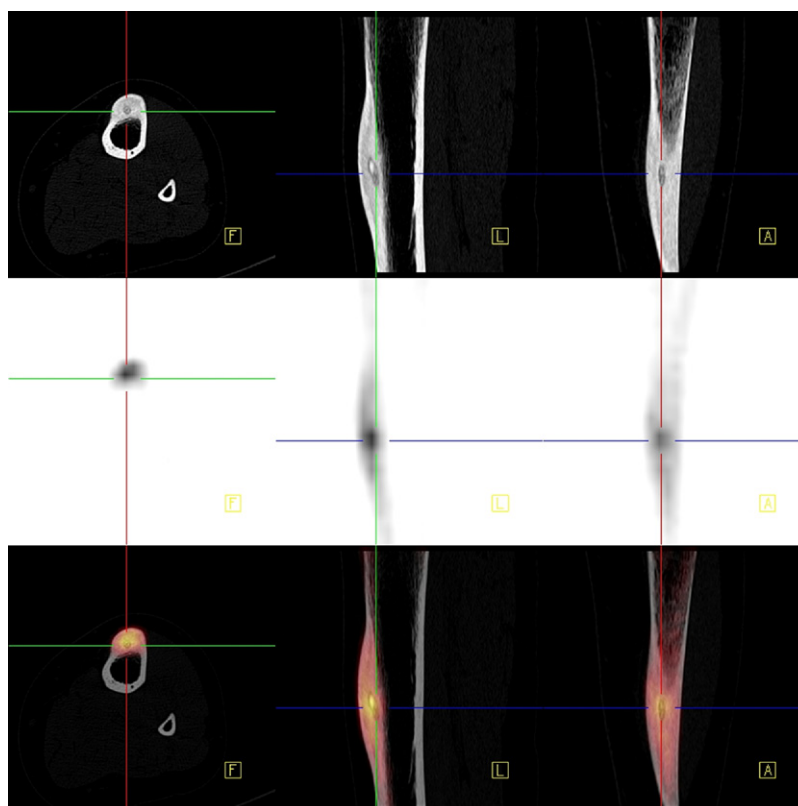
While many institutions employ magnetic resonance imaging for diagnosis of acute osteomyelitis, the bone scan is still an efficient study for evaluating for possible infection or inflammation of bone in children. Magnetic resonance imaging, while not using radiation, does often necessitate the use of sedation, which is not the routine for conventional bone scintigraphy, including SPECT, in our department. Evaluation for infection or inflammation includes a multiphase bone scan (either 3-phase study including flow, pools, and delayed imaging, or 2-phase study eliminating the flow phase). The diagnosis of osteomyelitis is made with abnormalities detected on immediate and delayed imaging. The addition of 24 hour imaging of the site of possible involvement can often help to distinguish between osteomyelitis and cellulitis. Cellulitis typically shows clearing of the soft tissue activity at 24 hours. With current generation of gamma cameras, good high-resolution images to detect bone infection can be obtained in all age children including neonates provided there is careful attention to technical detail. Bone scintigraphy in suspected osteomyelitis should not be obtained with a less than 24-hour history of symptoms, as the scan may not be as sensitive to detect abnormality before this time frame. It is important to remember that in children under 2 years of age osteomyelitis has a hematogenous dissemination and can present as multifocal disease (Fig. 11).

Another form of multifocal involvement can be observed in chronic nonbacterial osteomyelitis in which no pathogen is found when the involved areas undergo biopsy.<sup>14-17</sup> This entity usually occurs in teenagers with a female preponderance. The scintigraphic findings are similar to that for conventional osteomyelitis. Common sites of involvement are the metaphyseal portions of the long bones, medial ends of the clavicles, face, spine pelvis, and upper extremities. When the disease is quiescent the bone scan of previously involved sites may be negative.

## Neoplasm

Bone scintigraphy with SPECT is still indicated for children with primary bone neoplasms to include osteosarcoma and Ewing sarcoma for staging evaluation to assess for bone metastasis and skip lesions at presentation as per Children's Oncology Group imaging guidelines for these tumors.<sup>18</sup> PET/CT may eventually replace bone scintigraphy for staging evaluation but as yet there is no consensus that PET/CT should be the only study performed in suspected primary bone tumors. MDP bone scan is also recommended for end of treatment evaluation for children with osteosarcoma and if previously positive in children with Ewing sarcoma. For routine surveillance in high risk patients who have completed treatment bone scan should be performed when directed by new symp-





**Figure 12** CT, bone SPECT, and fused SPECT/CT images in transaxial, coronal, and sagittal planes of an osteoid osteoma of the tibia in a boy presenting with night pain. The images show the central nidus as an area of increased density within a lucent area in the focal cortical thickening on the CT images that corresponds with the hottest area of bone scan activity producing a “double-density” sign in this patient with an osteoid osteoma.

toms or abnormal findings on other imaging studies unless PET/CT has already shown recurrent or metastatic disease.

Benign lesions such as fibrous dysplasia, osteoid osteoma, and Langerhan’s cell histiocytosis will still benefit from bone scintigraphic evaluation. Fibrous dysplasia lesions whether mono or polyostotic are among the most intensely avid lesions observed on MDP bone scintigraphy. Osteoid osteoma can be readily evaluated with SPECT/CT before treatment (Fig. 12). In Langerhan’s cell histiocytosis the bone lesions may show increased activity, decreased activity, or not be detected by conventional bone scan. Therefore, there is continued requirement to perform both radiographic skeletal survey and bone scintigraphy at diagnosis and to follow the patient with the study that best detects the sites of disease.

Scintigraphy of the musculoskeletal system has always provided a very sensitive way to identify areas of abnormality of bones and soft tissues with three-phased assessment. Increased specificity is now derived from the addition of hybrid imaging to diagnose abnormalities that may be due to infection, trauma, and tumor in children. The future of bone scintigraphy in pediatrics is still secure.

## References

1. Even-Sapir E, Flusser G, Lerman H, et al: SPECT/multislice low-dose CT: A clinically relevant constituent in the imaging algorithm of non-oncologic patients referred for bone scintigraphy. *J Nucl Med* 48:319-324, 2007
2. Scharf S: SPECT/CT imaging in general orthopedic practice. *Semin Nucl Med* 39:293-307, 2009
3. Van der Wall H, Fogelman I: Scintigraphy of benign bone disease. *Semin Musculoskelet Radiol* 11:281-300, 2007
4. Nadel HR: Bone scan update. *Semin Nucl Med* 37:332-339, 2007
5. Jacobs F, Thierens H, Piepsz A, et al: Optimised tracer-dependent dosage cards to obtain weight-independent effective doses. *Eur J Nucl Med Mol Imaging* 32:581-588, 2005
6. Lassmann M, Biassoni L, Monsieurs M, et al: The new EANM paediatric dosage card. *Eur J Nucl Med Mol Imaging* 34:796-798, 2007
7. Treves ST, Davis RT, Fahey FH: Administered radiopharmaceutical doses in children: a survey of 13 pediatric hospitals in North America. *J Nucl Med* 49:1024-1027, 2008
8. Even-Sapir E, Mishani E, Flusser G, et al: 18F-fluoride positron emission tomography and positron emission tomography/computed tomography. *Semin Nucl Med* 37:462-469, 2007
9. Grant FD, Fahey FH, Packard AB, et al: Skeletal PET with 18F-fluoride: applying new technology to an old tracer. *J Nucl Med* 49:68-78, 2008
10. Lim R, Fahey FH, Drubach LA, et al: Early experience with fluorine-18 sodium fluoride bone PET in young patients with back pain. *J Pediatr Orthop* 27:277-282, 2007
11. Diagnostic imaging of child abuse. *Pediatrics* 123:1430-1435, 2009
12. Driessens M, Dijks H, Verheyen G: What is reflex sympathetic dystrophy? *Acta Orthop Belg* 65:202-217, 1999
13. Oud CF, Legein J, Everaert H: Bone scintigraphy in children with persistent pain in an extremity, suggesting algoneurodystrophy. *Acta Orthop Belg* 65:364-366, 1999
14. Giedion A, Holthusen W, Masel LF, et al: [Subacute and chronic “symmetrical” osteomyelitis]. *Ann Radiol (Paris)* 15:329-342, 1972

15. El-Shanti HI, Ferguson PJ: Chronic recurrent multifocal osteomyelitis: a concise review and genetic update. *Clin Orthop Relat Res* 462:11-19, 2007
16. Jurriaans E, Singh NP, Finlay K, et al: Imaging of chronic recurrent multifocal osteomyelitis. *Radiol Clin North Am* 39:305-327, 2001
17. Mandell GA, Contreras SJ, Conard K, et al: Bone scintigraphy in the detection of chronic recurrent multifocal osteomyelitis. *J Nucl Med* 39:1778-1783, 1998
18. Meyer JS, Nadel HR, Marina N, et al: Imaging guidelines for children with Ewing sarcoma and osteosarcoma: a report from the Children's Oncology Group Bone Tumor Committee. *Pediatr Blood Cancer* 51: 163-170, 2008